

"The human spirit is stronger than anything that can happen to it."

- C.C. Scott



radiology

dedicated to care

# THE IMPORTANCE OF *Mammography*

*A guide to taking care of your breasts*



## Thursday: Mammogram

*Is this a true picture does it  
give a good likeness  
did you get my left side  
is it better than my right?  
Like the portrait painters of old have you  
exaggerated my eyes – compensated  
for an overbite?*

Stand still please.  
The camera does not lie.  
We will capture you  
just as the world sees you,  
no better, no worse.  
Move left please.  
A little higher. A little  
closer to the machine.

There.

Now we have you.

- a poem from *Missing* by Beverly Rycroft

## WHAT IS BREAST CANCER?

Breast cancer is a process whereby a group of abnormal cells grow and invade healthy cells of the breast. These abnormal cells can spread to surrounding tissue or to other parts of the body. Nobody knows the exact cause of breast cancer, but women with certain risk factors may, however, have an increased chance of developing breast cancer. Many women who have risk factors may never develop cancer. Most risk factors cannot be modified, while some are modifiable.

## FACTS ABOUT BREAST CANCER

- Breast cancer incidences and death rates have increased over the last three decades.
- Breast cancer is currently the most frequently diagnosed cancer among women and the 5<sup>th</sup> highest cause of cancer related deaths.
- An estimated 2.3 million new cases are diagnosed globally each year according to GLOBOCAN 2020 data.
- This highlights the importance of breast health awareness, regular screening and early detection.

## MALE BREAST CANCER

Males do not develop milk-producing breasts. A man's breast tissue can, however, develop cancer. Male breast cancer is very rare and risk factors include:

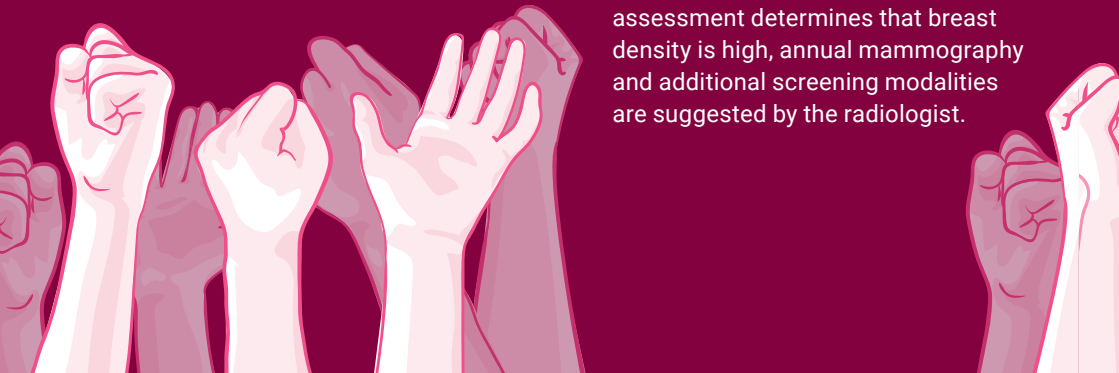- Radiation exposure.
- High levels of the hormone oestrogen.
- Family history of breast cancer (particularly the BRCA 2 gene mutation).

Male breast cancer usually presents as a lump related to the chest wall in the vicinity of the nipple.

# RISK FACTORS FOR BREAST CANCER

## 1. NON-MODIFIABLE FACTORS

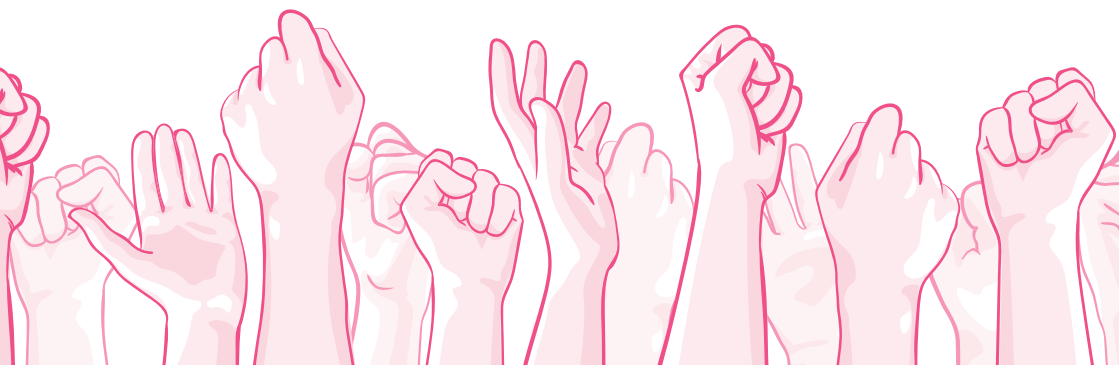- **Female sex:** Women have breast cells which are extremely vulnerable to hormones (oestrogen and progesterone). Increased circulating hormones are associated with an increased risk for breast cancer.
- **Older age:** The risk (excluding intermediate and high risk individuals) of developing breast cancer is 1.5% at the age of 40, 3% at age 50 and >4% at age 70.
- **Family history:** Approximately 13-19% of newly diagnosed patients have a first degree relative known with breast cancer. The risk increases with an increase in number of affected first degree relatives and may be even higher if the affected relatives are younger than 50 years old.
- **Genetic mutations:** Numerous genetic mutations and syndromes are associated with an increased risk of breast cancer. BRCA1 and BRCA2 being the two major mutations.
- **Race/ethnicity:** Significant differences regarding ethnicities and races are appreciated globally.
- **Reproductive history:** Nulliparity (when a woman has never carried a pregnancy) increases a woman's risk of breast cancer and every live birth reduces the relative risk by about 7%. Women 30 years or older at the time of their first live birth have a higher risk of breast cancer than women who have had their first child at a younger age. Increased duration of breastfeeding has a protective effect. The relative risk of breast cancer decreases by about 4% for every 12 months of breastfeeding.
- **Menarche and menopause:** Women with an earlier age of menarche (first menstruation) and/or a later age of menopause have an increased risk of breast cancer. This is due to the increased number of menstrual cycles and the longer lifetime exposure to oestrogen and progesterone.
- **Breast density:** Breast density is a mammographic finding. Dense breast tissue is known to limit the sensitivity of mammographic screening. Women with extremely dense breasts have about a twofold increased risk compared to women with breasts of average density. When a radiological assessment determines that breast density is high, annual mammography and additional screening modalities are suggested by the radiologist.



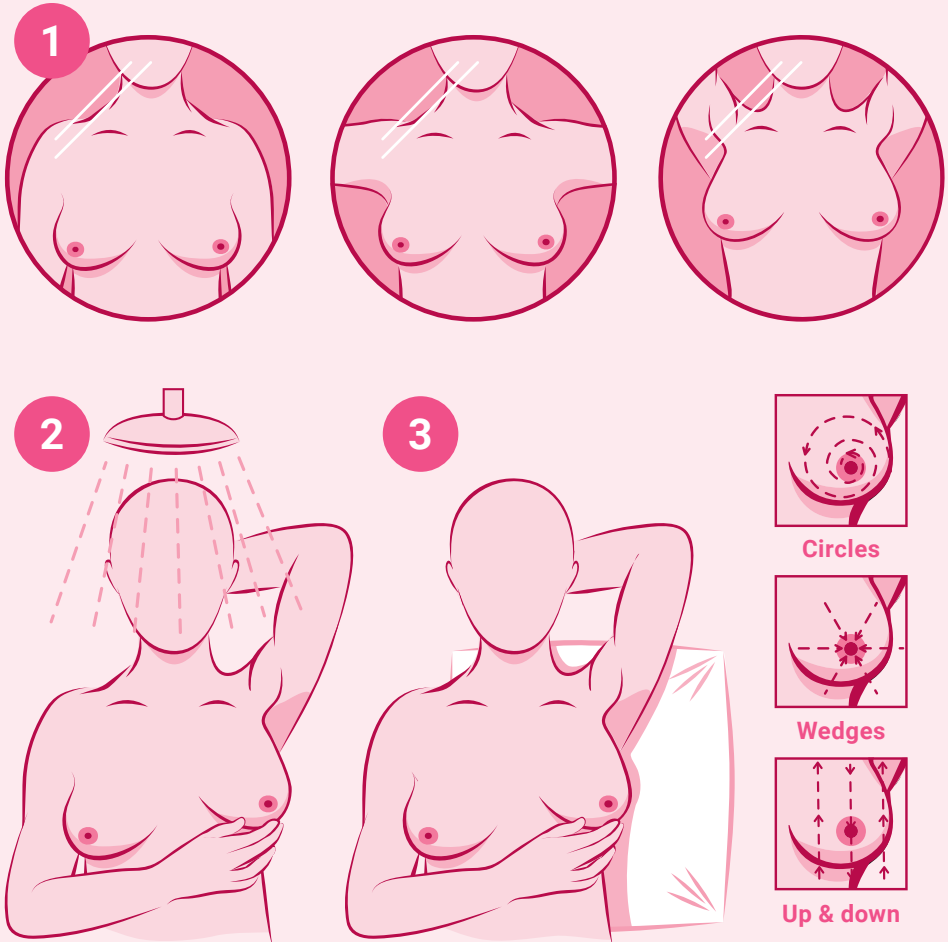
- **Previous radiation therapy:** Women with a history of chest wall radiation as treatment for another cancer have up to ten times increased risk for developing breast cancer later on in life. The risk varies according to the age at which the patient received radiation therapy and is highest if the radiation was given before menarche (first menstruation).

## 2. MODIFIABLE FACTORS

- **Hormone replacement therapy:** Among women who use combination oestrogen-progesterone hormone replacement therapy (HRT), the risk of breast cancer increases with the length of use. After five years of using combined HRT, the risk of breast cancer increases by about 15%, and the risk returns to baseline within about two years of stopping HRT. Oestrogen therapy alone increases breast cancer risk as well, but the increased risk is lower than for combined therapy.
- **Physical activity:** Breast cancer risk is reduced among physically active women.
- **Overweight/obesity:** Obesity is associated with an increased risk of postmenopausal breast cancer. Obesity also negatively affects prognosis of early-stage breast cancer.
- **Alcohol intake:** Regular consumption of as little as one drink per day elevates the risk of breast cancer. The risk increases steadily with increasing consumption regardless of the type of alcohol consumed.
- **Smoking:** There is an association between active smoking and breast cancer. There is also an association between secondhand smoke and breast cancer among younger, primarily premenopausal women.
- **Increased risk may be associated with**
  - Insufficient vitamin supplementation
  - Intake of excessive processed foods
  - Exposure to chemicals
  - Other prescribed medication



# SELF-EXAMINATION



**A monthly self-examination is recommended.  
Regular clinical examination by a doctor should also be scheduled.**

1

### IN FRONT OF A MIRROR

Examine your breasts with your arms at your sides. Then raise your arms high above your head and look for any changes in the contour, any swelling or skin dimpling or changes related to the nipples. Following this, rest your palms on your hips and press firmly to flex your chest muscles. Asymmetry of the breasts is a normal finding. Look for new changes in size, skin dimpling or puckering, particularly on one side.

2

### IN THE SHOWER

Using the pads of your fingers, feel around your entire breast and under the arm in a circular pattern, moving from the outside to the centre. Examine both breasts each month, feeling for any lump or thickening.

3

### LYING DOWN

Place a pillow under your right shoulder and your right arm behind your head. Using your left hand, move the pads of your fingers around your right breast gently and in small circular motions, covering the entire breast area and underarm. Use light, medium, and firm pressure. Feel for any lump or thickening. Then gently squeeze the nipple to check for a nipple discharge. Repeat these steps for your left breast.





## SYMPTOMS & WARNING SIGNS

### 1. CHANGES RELATED TO THE BREAST AND UNDERARM

- Unexplained, sudden or new onset changes in the size and shape of the breast (enlargement or shrinkage, particularly if only on one side)
- Scaly, red, swollen skin related to the nipple-areola complex
- Skin changes (orange peel texture/enlarging pores)
- A lump or thickening within the breast or underarm
- Skin dimpling

### 2. CHANGES RELATED TO THE NIPPLE

- Nipple tenderness
- New inverted nipple (particularly if only on one side)
- Nipple discharge (particularly if only on one side)
- Bloody, dark brown and clear discharges are considered worrisome
- Milky and green discharges are usually less concerning


### 3. BREAST PAIN

- Breast pain could be any discomfort, tenderness or pain in the breast or underarm region. Generally, breast pain is not a sign of breast cancer. There are several harmless causes of breast pain and tenderness that may primarily be related to changes in hormone levels. Certain medication may also contribute to breast pain. Breast pain associated with the following examples is considered worrisome and requires further investigation:
- Bloody or clear nipple discharge
- Nipple in-drawing/changes to the nipple and areola
- Skin dimpling or puckering
- Skin thickening
- A new lump with the onset of the pain which does not go away after your menstrual period
- Signs of a breast infection (local redness, pus or fever)
- Frequent and unexplained pain

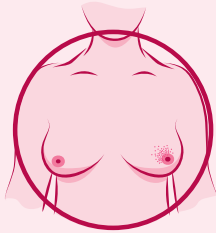




A lump or thickening that feels different from the rest of your breast



Your nipple becomes inverted (pulled in) or changes shape




A rash or redness on the skin around your nipple



A change in skin texture, such as dimpling



Discharge (liquid) from your nipple



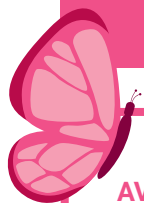Swelling in your armpit or around your collarbone

## IMAGING

- **Digital Mammography:** Breast imaging using low dose X-rays to form a 2D image. It has the advantage of revealing abnormalities undetected on clinical breast examination. Mammography is used as a primary screening or diagnostic tool.
- **Digital Breast Tomosynthesis or 3D Mammogram:** Breast imaging modality using X-rays and sophisticated digital software to create a 3D image of the breast. It is used for problem solving and screening in combination with a 2D mammogram.
- **Breast Ultrasound:** Real time imaging using sound waves to create an image. No radiation. It may be used as an additional (or primary) screening or diagnostic tool.
- **MRI:** A digital image is created using a strong magnetic field and radio waves. No radiation. It is used for problem solving, high risk screening and breast implants.

# ADAPTED ACR *(American College of Radiologists)*

## SCREENING GUIDELINES



### FOR AVERAGE-RISK WOMEN

**Women with <15% lifetime risk of breast cancer**

- All women should have a risk assessment by age 30 years.
- Annual screening mammography starting at age 40 years.
- Women aged 55 years and older have the choice to screen with mammography every 2 years or continue yearly mammographic screening.
- Women older than 75 years - no upper age limit for mammographic screening unless severe comorbidities limit life expectancy.

### FOR INTERMEDIATE- RISK WOMEN

**Women with a 15% to 20% lifetime risk of breast cancer**

- (personal history of breast cancer, lobular neoplasia, atypical ductal hyperplasia, flat epithelial atypia, heterogeneously dense and extremely dense breast tissue).
- Annual screening mammography starting at age 40 years or from the time of diagnosis regardless of age.
  - MRI can be performed where appropriate.

### FOR HIGH-RISK WOMEN

**Women with a 20% or greater lifetime risk of breast cancer**

- (BRCA gene mutation and their untested first-degree relatives, other high risk gene mutations/genetic syndromes and women with a history of chest irradiation between 10 to 30 years of age).
- Six monthly screening with alternate mammography and MRI starting at age 25-30 years;
  - or 10 years earlier than the age at which the youngest first degree relative was diagnosed (not before 25 years);
  - or 8 years after radiation (not before 25 years).

# MY MAMMOGRAM REPORT

**Your mammogram report should include your breast density.** Breast density refers to the amount of fibroglandular tissue (fibrous and glandular tissue) in the breast relative to fat. There is an increased risk of breast cancer associated with dense breasts. Mammograms may be less accurate with dense breast tissue and you will need additional imaging.

**Breast density is classified as follows:**

- A. Fatty (almost entirely fat)
- B. Scattered (scattered areas of fibroglandular tissue which make up less than 50% of your breast)
- C. Heterogenous (fibroglandular tissue makes up 50-75% of your breast)
- D. Extremely dense (fibroglandular tissue makes up more than 75% of your breast)

**Your mammogram report should include your BI-RADS classification**

(A standardised system to describe findings and results).

**BI-RADS 0:** Additional or previous imaging needed

**BI-RADS 1:** Negative

**BI-RADS 2:** Benign (not cancer) finding

**BI-RADS 3:** Abnormal finding that is probably benign. Short interval 6 month follow up recommended

**BI-RADS 4 and 5:** Suspicious finding. Biopsy recommended

**BI-RADS 6:** Known biopsy proven cancer

**Your mammogram report may describe cysts, nodules, masses, calcifications or architectural distortion.**

## WHAT IS A BREAST CYST?

A cyst in the breast may feel like a lump. Ultrasound may reveal a cyst or group of cysts. A simple cyst is a harmless sac filled with fluid. They are almost never associated with a higher risk of cancer.

## WHAT ARE NODULES AND MASSES?

A nodule is a small solid lump in your breast. A mass is a large solid lump in your breast. Masses are usually easily felt. New nodules and masses may raise concern. However, **Not all** nodules and masses are cancer.

## WHAT IS ARCHITECTURAL DISTORTION?

Architectural distortion is a term used to describe an area of the breast in which the normal structure of the breast tissue is distorted. It is an abnormal finding which may raise concern, particularly if it is new or there is no history of previous surgery. **Not all** architectural distortion is cancer.

## WHAT ARE CALCIFICATIONS?

These are specks of calcium seen on a mammogram. They can be harmless, but some calcifications are, however, associated with cancer. A biopsy will be recommended if the radiologist is concerned.

## Branches where mammography is performed

### **SCP Radiology Cape Gate**

Mediclinic Cape Gate  
c/o Okavango and Tanner Roads  
Brackenfell  
T. 021 983 1680

### **SCP Radiology Ceres**

Ceres Netcare Hospital  
2 Faure Street, Ceres  
T. 023 316 1502

### **SCP Radiology Durbanville**

Mediclinic Durbanville  
Wellington Road, Durbanville  
T. 021 975 3962

### **SCP Radiology Louis Leipoldt and MRI**

Mediclinic Louis Leipoldt, Room 306  
7 Broadway Street, Bellville  
T. 021 948 5951

### **SCP Radiology Paarl**

Mediclinic Paarl, Room 6  
Berlyn Street, Paarl  
T. 021 872 3049

### **SCP Radiology Panorama**

Mediclinic Panorama, Room G08  
Rothschild Boulevard, Panorama  
T. 021 930 4460

### **SCP Radiology Swellendam**

134 Voortrek Street, Swellendam  
T. 028 514 3929

### **SCP Radiology Tygervally Mammography Centre**

Shop B, Gihon Building, Ground Floor  
Cnr Sportica Crescent &  
Bill Bezuidenhout Avenue, Bellville  
T. 021 100 6140

### **SCP Radiology Vredenburg**

Life Healthcare Hospital  
Voortrekker Street, Vredenburg  
T. 022 713 4431

### **SCP Radiology Worcester**

Worcester Mediclinic  
67 Fairbairn Street, Worcester  
T. 023 347 0923